



Fetal Pig Dissection



Background:

Mammals are vertebrates having hair on their body and mammary glands to nourish their young. The majority are placental mammals in which the developing young, or fetus, grows inside the female's uterus while attached to a membrane called the placenta. The placenta is the source of food and oxygen for the fetus, and it also serves to get rid of fetal wastes. The dissection of the fetal pig in the laboratory is important because pigs and humans have the same level of metabolism and have similar organs and systems. Also, fetal pigs are a byproduct of the pork food industry so they aren't raised for dissection purposes, and they are relatively inexpensive.

Objectives:



- Identify important external structures of the fetal pig.
- Identify major structures associated with a fetal pig's digestive, respiratory, circulatory, urogenital, & nervous systems.
- Compare the functions of certain organs in a fetal mammal with those of an adult mammal.


Class Copy



Materials:

preserved fetal pig, dissecting pan, dissecting kit, dissecting pins, string, plastic bag, metric ruler, paper towels

*****Wear your lab apron and eye cover at all times. Watch your time and be sure to clean up all equipment and working area each part before leaving.**



Part 1 - External Anatomy

1. Obtain a fetal pig. Lay the pig on its side in the dissecting pan and locate dorsal, ventral, & lateral surfaces. Also locate the anterior and posterior ends.
2. A fetal pig has not been born yet, but its approximate age since conception can be estimated by measuring its length. Measure your pig's length from the tip of its snout to the base of its tail and record this on your hand-out. Use the length/age chart on this sheet or the inside cover of your dissection manual to determine the age of your fetal pig & record this.
3. Examine the pig's head. Locate the eyelids and the external ears or pinnae. Find the external nostrils.
4. Study the pig's appendages and examine the pig's toes. Count and record the number of toes and the type of hoof the pig has.
5. Locate the umbilical cord. With scissors, cut across the cord about 1 cm from the body. Examine the 3 openings in the


Class Copy

umbilical cord. The largest is the umbilical vein, which carries blood from the placenta to the fetus. The two smaller openings are the umbilical arteries which carry blood from the fetus to the placenta.

6. Lift the pig's tail to find the anus. Study the ventral surface of the pig and note the tiny bumps called **mammary papillary**. These are present in both sexes. In the female these structures connect to the mammary glands.
7. Determine the sex of your pig by locating the urogenital opening through which liquid wastes and reproductive cells pass. In the male, the opening is on the ventral surface of the pig just posterior to the umbilical cord. In the female, the opening is ventral to the anus. Record the sex of your pig.
8. Carefully lay the pig on one side in your dissecting pan and cut away the skin from the side of the face and upper neck to expose the **masseter muscle** that works the jaw, **lymph nodes**, and **salivary glands**. Label these on your hand-in.
9. With scissors, make a 3-cm incision in each corner of the pig's mouth. Your incision should extend posteriorly through the jaw.
10. Spread the jaws open and examine the tongue.
11. Observe the **palate** on the roof of the mouth. The anterior part of the palate is the hard palate, while the posterior part is the soft palate.
12. Locate the **epiglottis**, a cone-shaped structure at the back of the mouth. Above the epiglottis, find the round opening of the **nasopharynx**. This cavity carries air from the nostrils to the **trachea**, a large tube in the thoracic which supplies air to the lungs.
13. Dorsal to the **glottis**, find the opening to the esophagus. Examine the tongue and note tiny projections called **sensory papillae**.

Class Copy

14. Examine the teeth of the pig. **Canine** teeth are longer for tearing food, while **incisor** are shorter and used for biting. Pigs are **omnivores**, eating plants and animals.
15. Label the drawing of the inside of the pig's mouth.



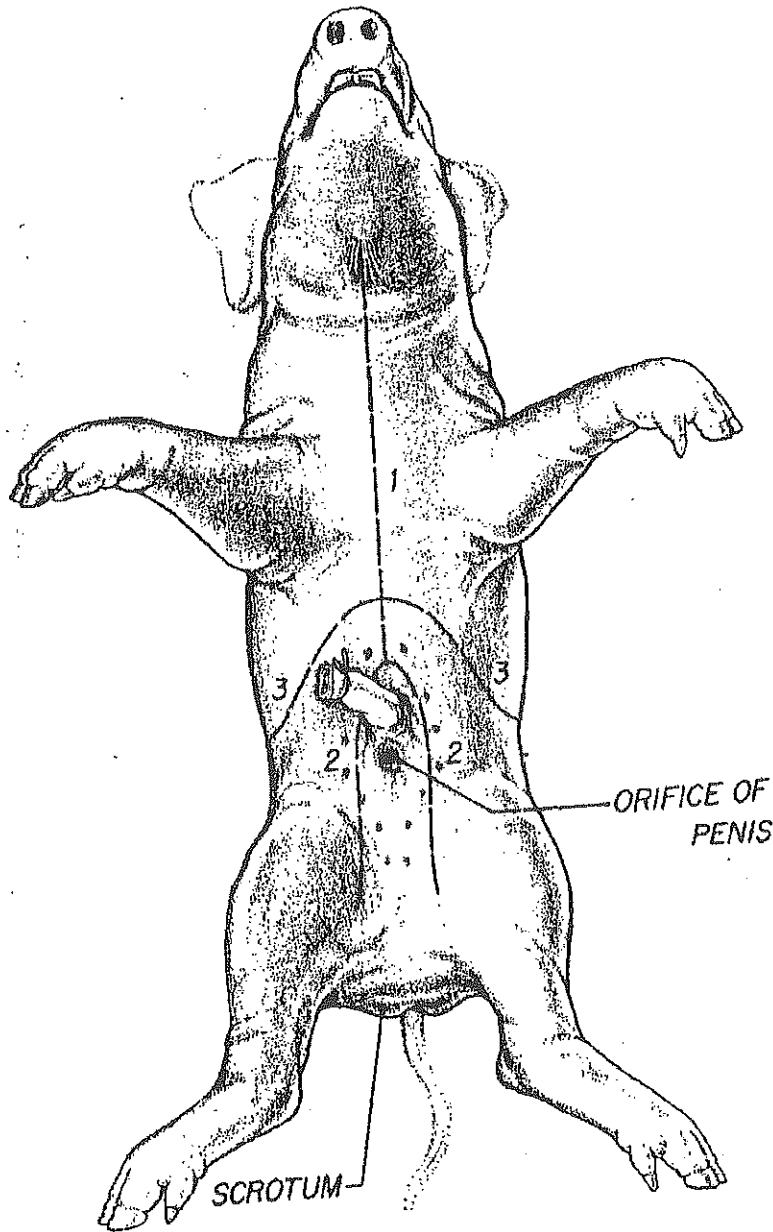
Part 2

Part A: The Incision

1. Be sure to wear your lab apron and eye cover. Obtain your dissecting equipment and pig.
2. Place the fetal pig ventral side up in the dissecting tray.
3. Study the diagram below. The dashed lines numbered 1-5 show the first set of incisions that you will make. To find the exact location for the incision marked 2, press along the thorax with your fingers to find the lower edge of the ribs. This is where you will make incision 2.
4. With scissors, make the incisions in order, beginning with 1. Be sure to keep the tips of your scissors pointed upward because a deep cut will destroy the organs below. Also, remember to cut away from yourself.
5. After you have made your incisions through the body wall, you will see the peritoneum, a thin layer of tissue that lines the body cavity. Cut through the **peritoneum** along the incision lines.
6. Spread the flaps of the body wall apart. Cut the umbilical vein which extends through the liver.
7. Once the vein is cut, carefully pull the flap of skin, including the end of the umbilical cord between the hind legs. You are now able to see the organs of the abdominal cavity.

Continue with part B, the digestive tract. Otherwise, clean up and return your materials and pig as you did on part 1.

Class Copy



Par

† B: Digestive System



1. Be sure you are wearing your lab apron and eye cover.
2. Locate the diaphragm, a sheet of muscle that separates the abdominal cavity from the thoracic cavity. Find the most

Class Copy

- obvious structure in the abdominal cavity, the brownish-colored **liver**. Count the number of lobes.
3. Find the tube-like **esophagus** which joins the mouth and the stomach. Food moves down the esophagus by muscular contractions after being softened by saliva in the mouth. Follow the esophagus and locate the soft, sac-like **stomach** beneath the liver.
 4. With scissors, cut along the outer curve of the stomach. Open the stomach and note the texture of its inner walls. These ridges inside the stomach are called **rugae** and increase the area for the release of digestive enzymes. The stomach may not be empty because fetal pigs swallow amniotic fluid.
 5. The pig has a digestive system which is classified as **monogastric** or **nonruminant**. Humans also have this type of digestive system. They have one stomach (mono=one, gastric=stomach). Locate the entrance to the stomach or esophageal area, the **cardiac region** which is largest, and the **pyloric region** where the stomach narrows to join to the **small intestine**.
 6. At the end of the stomach, there is a **sphincter**, or ring-shaped muscle to control food leaving the stomach and entering the **duodenum**. Locate the cardiac sphincter at the junction of the stomach and esophagus, and the pyloric sphincter at the junction of the stomach and small intestine. Fetal pigs receive their nourishment from their mother through the umbilical cord.
 7. Identify the first part of the small intestine, the U-shaped duodenum, which connects to the lower end of the stomach. Pancreatic juice, made by the **pancreas**, and bile, made by the liver and stored in the **gall bladder**, are add to food here to continue digestion.
 8. Study the rest of the small intestine. Notice that it is a coiled, narrow tube, held together by tissue called **mesentery**.


Class Copy

The soupy, partly digested food that enters the small intestine from the stomach is called **chyme**.

9. Carefully cut through the mesentery and uncoil the small intestine. Note and record its length in centimeters. The mid-section is called the **jejunum**, while the last section is called the **ileum**.
10. With scissors, remove a 3-cm piece of the lower small intestine. Cut it open and rinse it out.
11. Observe the inner surface of the small intestine. Run your finger along it and note its texture. Using a magnifying glass, examine the **villi**, the tiny projections that line the small intestine and increase the surface area for absorption.
12. Follow the small intestine until it reaches the wider, looped **large intestine**. Cut the mesentery and unwind the large intestine or **colon**. Measure and record its length.
13. At the junction of the large and small intestine, locate a blind pouch called the **caecum**. The caecum has no known function in the pig.
14. Notice that the large intestine leads into the **rectum**, a tube that runs posteriorly along the dorsal body wall. The rectum carries wastes to the opening called the **anus** where they are eliminated.
15. Locate the thin, white **pancreas** beneath the stomach and duodenum. Pancreatic juice flows through pancreatic ducts to the duodenum.
16. Between the lobes of the liver, find the small, greenish-brown **gall bladder**. Locate the hepatic duct which carries bile from the liver to the gall bladder.
17. Find the **spleen**, a long, reddish-brown organ wrapped around the stomach. The spleen filters out old red blood cells and produces new ones for the fetus.
18. On the diagram on the back of part 2 hand-in, label the pig's body organs.

Class Copy

Part 3 *Respiratory System*




1. Be sure to wear your lab apron and eye cover.
2. Examine the **diaphragm**, a sheet of muscle that stretches across the abdominal cavity and separates it from the thoracic cavity where the lungs are located. The diaphragm isn't used by the fetal pig because gas exchange occurs through the umbilical cord. The diaphragm in adult pigs moves up and down changing air pressure in the chest cavity causing air to move into and out of the lungs.
3. In order to see the upper part of the respiratory system, you will need to extend cut #1 up under the pig's throat and make to more lateral incisions in order to fold back the flaps of skin covering the throat.
4. In the thoracic cavity, carefully separate the pericardium or sac surrounding the heart and the diaphragm from the body wall.
5. Locate the two, spongy lungs that surround the heart. The tissue that covers and protects the lungs is called **pleura**. The lungs haven't been used by the fetus so they have never contained air.
6. Find the **trachea**, a large air tube that lies anterior to the lungs. The trachea is easy to identify because of the **cartilaginous rings** that help keep it from collapsing as the animal inhales and exhales.
7. Notice that the trachea branches into each lung. These two tubes are called **bronchial tubes**. Inside the lungs these branch into smaller **bronchioles** that end with a grape-like

Class Copy

cluster of air sacs or **alveoli** where oxygen and carbon dioxide are exchanged with capillaries.

8. Lying ventral to the trachea or windpipe, locate the pinkish-brown, V-shaped structure called the **thyroid gland**. This gland secretes hormones that control metabolism.
9. At the top, anterior end of the trachea, find the hard, light-colored **larynx** or voice box. This organ contains the **vocal cords** that enable the animal to produce sound.
10. Locate the **epiglottis** at the top of the trachea. This flap of skin closes over the trachea whenever you swallow. Find the area called the **pharynx** at the back of the nasal cavity. Air enters an adult pig through the mouth or nose before passing through the pharynx and down the trachea to the lungs.
11. Label the diagram of the respiratory system on your part 3 hand-in.

Part 4 *Circulatory System*




1. Be sure to wear your lab apron and eye cover.
2. Locate the heart. It is covered by a thin tissue called the **pericardium**. Remove this membrane to study the heart.
3. Pigs, like all mammals, have four-chambered hearts. The right side of the heart pumps blood to the lungs, while the left side of the heart pumps blood to all other parts of the body. Locate the right and left sides of the heart.
4. Each side of the heart has an upper and a lower chamber. Upper chambers are called **atria** and receive blood, while lower chambers are called **ventricles** and pump blood out of the heart. Locate the right and left atria and ventricle.

Class Copy

5. Notice that the surface of the heart is covered with blood vessels. These are part of the **coronary circulation**, a set of arteries and veins whose only job is to nourish the heart tissue. Blockage in these vessels causes heart attacks.
6. Anterior to the heart, locate another large vein that enters the right atrium. This vein, the **anterior vena cava**, brings blood to the right atrium from the anterior part of the body.
7. Now lift the heart to view its dorsal surface. Observe the **posterior vena cava** that carries blood from the posterior part of the body and empties it into the right atrium.
8. Find the **pulmonary artery** which leaves the right ventricle. After birth, this vessel carries blood to the lungs. However, in a fetus, a shunt called the **ductus arteriosus** allows fetal blood to bypass the lungs and go directly to the aorta, the largest artery of the body.
9. Locate the **pulmonary veins** that enter the left atrium. After birth, these vessels carry oxygenated blood from the lungs to the heart.
10. Identify the aorta, a large artery that transports blood from the left ventricle. Many arteries that carry blood throughout the body branch off of the
11. Remove the heart by severing the blood vessels attached to it.
12. Hold the dorsal and ventral surfaces of the heart with your thumb and forefinger and rest the ventricles on your dissecting tray. With a scalpel, cut the heart into dorsal and ventral halves. **Caution: The scalpel is very sharp. Use it carefully and always cut away from yourself.**
13. Remove any material inside the heart and expose the walls of the atria and the ventricles.
14. Study the internal features of these chambers and note where vessels leave or enter each chamber. Locate the valves between each atrium and ventricle. These structures prevent blood from flowing backward in the heart.
15. Label the fetal pig heart diagram on your part 4 hand-in.

Class Copy

Part 5 Urogenital System



1. Be sure to wear your lab apron and eye cover.
2. Remove the digestive organs to study the excretory and reproductive organs that make up the **urogenital system**.
3. Locate the large, bean-shaped **kidneys** lying against the dorsal body wall. Notice that they are covered by the **peritoneum**. Kidneys filter wastes from blood.
4. Find the **ureters**, tubes which extend from the kidneys to the bag-like **urinary bladder**. The urinary bladder lies between the **umbilical arteries** and temporarily stores liquid wastes filtered from the blood.
5. Lift the urinary bladder to find the **urethra**, the tube which carries urine out of the body. Follow the urethra to the urogenital opening on the outside of the pig's body.
6. Make sure that incision #6 extends all the way to the anus but be careful to not cut too deep and damage the internal organs.
7. Follow the directions below for locating the excretory and reproductive organs in either a male or female pig. When you finish observing the organs in a pig of one sex, exchange specimens with another classmate to view the organs in a pig of the opposite sex.

Male System



Class Copy

8. In the male pig, locate the two **scrotal sacs** at the posterior end of the pig. If the pig is in the later stages of development, you will find a **testis** in each sac. If the pig is in an early stage of development, the oval-shaped testes will be in the abdominal cavity. These testes have not yet descended into the scrotal sacs.
9. On each testis, find the coiled **epididymis**. Sperm cells produced in the testis pass through the epididymis and into a tube called the **vas deferens**. This tube crosses over a ureter and enters the urethra.
10. Follow the urethra to the **penis**, a muscular tube lying just below the skin posterior to the umbilical cord. In mammals, the penis is the organ that transfers sperm.
11. Label the diagram of the male urogenital system on your part 5 hand-in.


Female System



12. In the female pig, find the two bean-shaped **ovaries** at the posterior end of the abdominal cavity. Observe the coiled **Fallopian tube** attached to each ovary, which carries eggs from the ovary.
13. Follow the Fallopian tube to the **uterus**. The uterus is dorsal to the urinary bladder and the urethra.
14. Trace the uterus to a muscular tube called the **vagina**. The vagina will appear as a continuation of the uterus. Sperm from the male are deposited into this organ during mating. The vagina and the urethra open into a common area called the **urogenital sinus**. This cavity opens to the outside at the urogenital opening.

Class Copy

15. Label the diagram of the female urogenital system on your part 5 hand-in.



Part 6 *Nervous System*

1. Be sure to wear your lab apron and eye cover.
2. With the pig dorsal side down, open both thoracic and abdominal flaps and locate the spinal column.
3. Select a site along the spine and remove any organs blocking your view of the spine. Using a scalpel, expose the spine and locate any emerging nerves. Trace one as far as you can into the body.
4. Place the pig dorsal side up in your dissecting tray. In the thoracic region, remove the skin and muscle to expose 10mm of the vertebral column.
5. Using forceps to grip the spine and scissors to cut, open the vertebral canal by cutting off the vertebral arch. Note the dura mater or outermost covering of the brain & spinal cord.
6. Make a second cut on the other side of this vertebrae, and fold the spine section upward so you can view the cross-section. Locate the white and gray matter, dorsal and ventral root, central canal, and a dorsal root ganglion.
7. With the dorsal side of the pig up, remove the skin from the entire skull.
8. Cut through the skull near the center being careful not to break the meninges or membranes covering and protecting the brain.
9. After the skull is open, chip away the pieces but do not use the scalpel blade for chipping.

Class Copy

10. When the brain is completely exposed, locate the 2 large hemispheres called the **cerebrum**. **Fissures** indenting the surface of the cerebrum are called **sulci** (sulcus, singular). **Gyri** (gyrus, singular) are ridges projecting outward from the surface.
11. Locate the **longitudinal fissure** or indentation that runs laterally between the right and left cerebral hemispheres. The **olfactory lobes** that control smell are at the front of the cerebrum. The cerebrum controls thinking, senses, etc.
12. Posterior to the cerebrum is the **cerebellum**. Locate the cerebellum and the **transverse fissure** that separates it from the cerebrum. The cerebellum consists of 2 lateral hemispheres and is involved with the control of muscles and coordination.
13. Find the fissure between the right and left cerebellum hemispheres called the **vermis**.
14. Carefully remove the brain from the skull in order to locate the hind section of the brain known as the **medulla oblongata**. The medulla connects the brain to the spinal cord and controls all vital functions of the body such as heart beat and breathing.
15. Label the diagrams of the brain and spinal cord on your part 6 hand-in.

Clean up your materials and work area. Dispose of your pig and then thoroughly wash your hands with soap. Don't forget to wipe down your desk!