

CLASS COPY

Our Amazing Eyes

Objectives

As a result of doing this lab, you should be able to recognize, state the location of, and function of:

Eyelids	Eyelashes	Choroid Coat	Aqueous Humor
Lachrymal (tear) Ducts	Eyebrows	Ciliary Body	Rectus Muscles
Pupil	Sclera	Retina	Oblique Muscles
Iris	Cornea	Vitreous Humor	Optic Nerve

Materials

Preserved Sheep/Cow Eye	Dissecting Tray	Binocular Dissecting Scope
Disposable Gloves (optional)	Pointed Scissors	High Intensity Lamp

Introduction

Your eyes are a marvel of design and function. They are highly complex, *living* sense organs containing, among other things, receptor cells that are stimulated by light. Visual images picked up by your eyes are translated into nervous impulses that are eventually interpreted by the brain. Amazingly, we not only "see" a very clear and precise image through our eyes, we also record this image in living color! Hopefully during this lab exercise, you will begin to appreciate how truly wonderful our sense of sight is.

External Anatomy

Look at your lab partner's eye and locate the following structures. Then label the drawing at the right.

Eyelids

Lachrymal (tear) Ducts - Look for tiny holes at the bottom, nose-side corner of the lower eyelid. These ducts drain tears into the nasal passages.

Blood Vessels (in the eye)

Pupil - This is the circular opening that allows light into the eye.

Iris - The iris is the pigmented portion of the eye that surrounds the pupil.

Eyelashes and Eyebrows

Dissecting the Eye

- Carefully cut away the excess tissue from around the eyeball. Much of this is connective tissue. Some is glandular tissue that makes up the tear glands.
- Look at Figure 2 on the next page to see where the six ocular muscles attach near the front of the eyeball. Then locate these muscles on your preserved eye.
- What is the function of each of these muscle pairs? (Be specific! You can figure out what a muscle does by pretending to pull on it. Which way would the eye move?)

Superior and Inferior Rectus Muscles _____

Lateral Rectus Muscles _____

Superior and Inferior Oblique Muscles _____

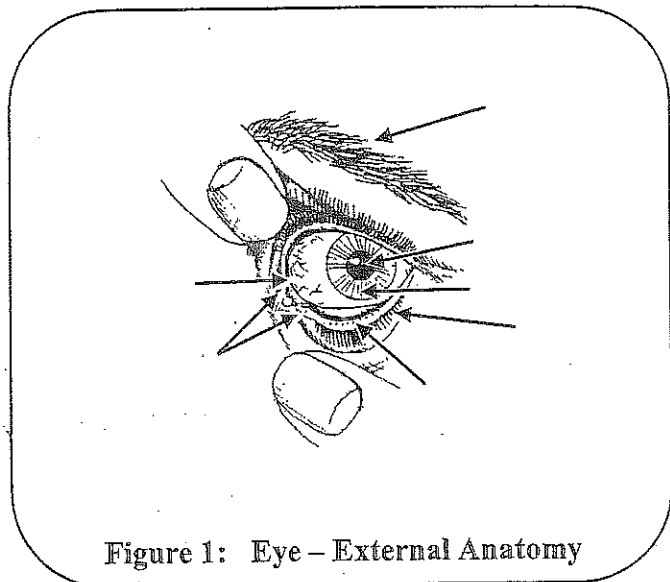


Figure 1: Eye – External Anatomy

*Illustrations adapted from Nasco International, Fort Atkinson, WI (920) 563-2446

The eyeball is made up of three tissue layers. The outer layer, the sclera, is opaque (semi-transparent) over most of the surface of the eye. The sclera is the white part of the eye. At the front of the eye, however, the sclera is transparent and forms the cornea (See Figure 2). In your preserved eye the cornea may be cloudy. Nevertheless, it is usually transparent enough to see the pigmented iris and a circular opening, the pupil (See Figures 2 and 3).

- To get a view of your preserved eye similar to that shown in Figure 3, take your fine pointed scissors and cut the eye in half slightly off-center so that you do not cut through the lens. Then locate the **Choroid Coat** - a dark pigmented layer just beneath the sclera. This layer is highly vascularized (= many blood vessels). Hence it is sometimes referred to as the **vascular tunic**. The dark pigmentation functions to trap extraneous light much like the black painted surfaces inside of a camera.

- Using the high intensity lamp, identify the pleated looking **ciliary body**. It is found around the outside edge of the lens and is attached to the lens by microscopic fibers. The ciliary body functions in changing the lens shape and in the secretion of watery aqueous humor into the anterior chamber.

- Next, locate the **retina**, - the inner layer of the eye. The retina contains the photosensitive receptor cells called rods and cones. These cells lie on the choroid (back) side of the retina. Thus light must pass through the retina to stimulate them.

- Notice three chambers within the eye (Figure 3). Locate the largest chamber between the lens and the retina. It is filled with a thick jelly-like fluid called the **vitreous humor**.

- The space between the lens and the iris is called the **posterior chamber**, while the space between the iris and the cornea is called the **anterior chamber**. These chambers contain a clear, water fluid called the **aqueous humor** that is continuously secreted by the ciliary body. Locate these chambers in your preserved eye.

- Finally, locate the **optic nerve** which emerges from the back of the eye. What is the relationship of this nerve to the eye and brain?

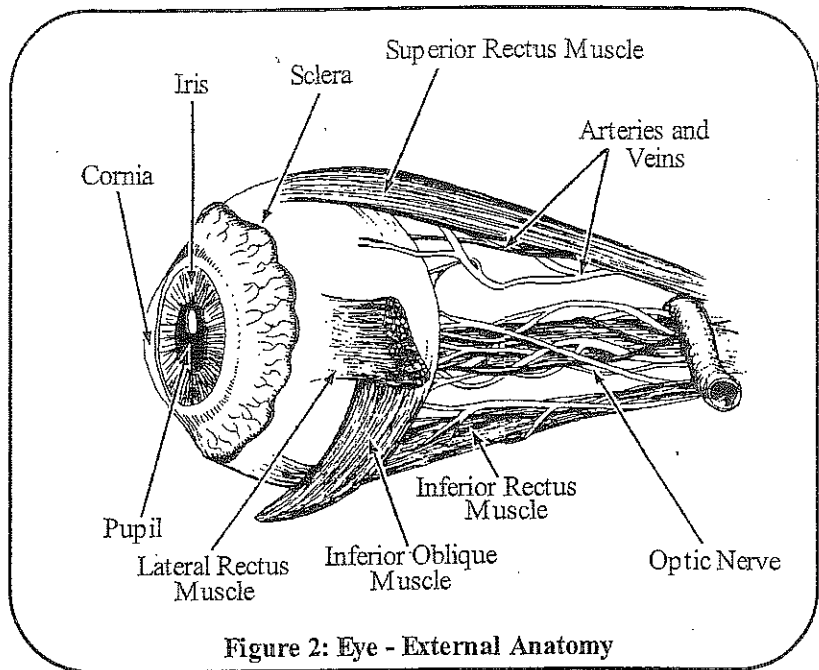


Figure 2: Eye - External Anatomy

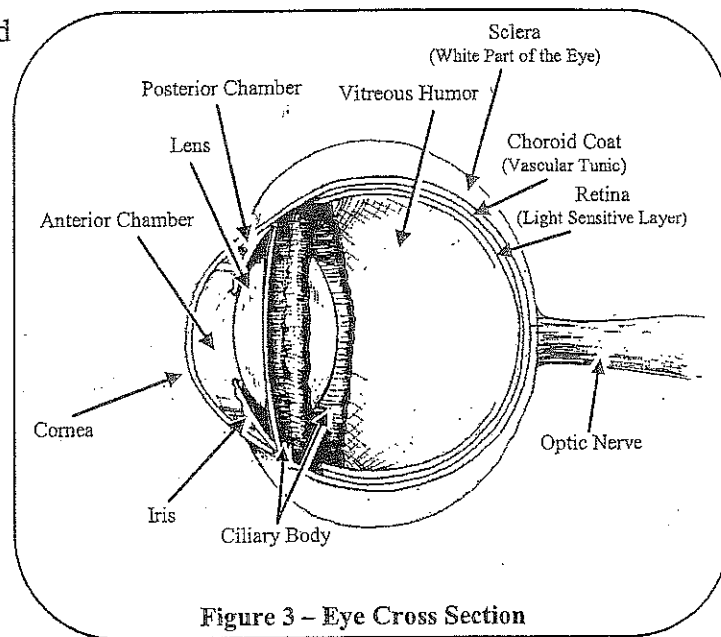


Figure 3 - Eye Cross Section

Analysis

- Your eyes are constantly supplied with tears from the lachrymal glands. Of what value are tears to the eye?

2. Discuss what you believe to be the function of the eyelashes and eyebrows.

3. What is the function(s) of the choroid coat? _____

4. What type of muscle orientation must be in the iris of the eye to regulate the diameter of the pupil?

5. Name the thick fluid in the largest eye chamber _____

6. What do you suppose is the function of this fluid? _____

7. How is the eye protected from a blow to the face? _____

For You to Research

Go to the library or use the Internet to answer the following questions. A good website is <http://www.allaboutvision.com/conditions/>

Chp. 15 - text

1. What is strabismus and how can it be corrected? _____

2. What is myopia and what is happening in the eye to cause it?

3. What is hyperopia and what is happening in the eye to cause it?

4. What is glaucoma and what should people do as they get older to prevent it?

5. What is conjunctivitis, how does one get it, and how is it treated?

6. What is macular degeneration? What are some potential treatments?
